
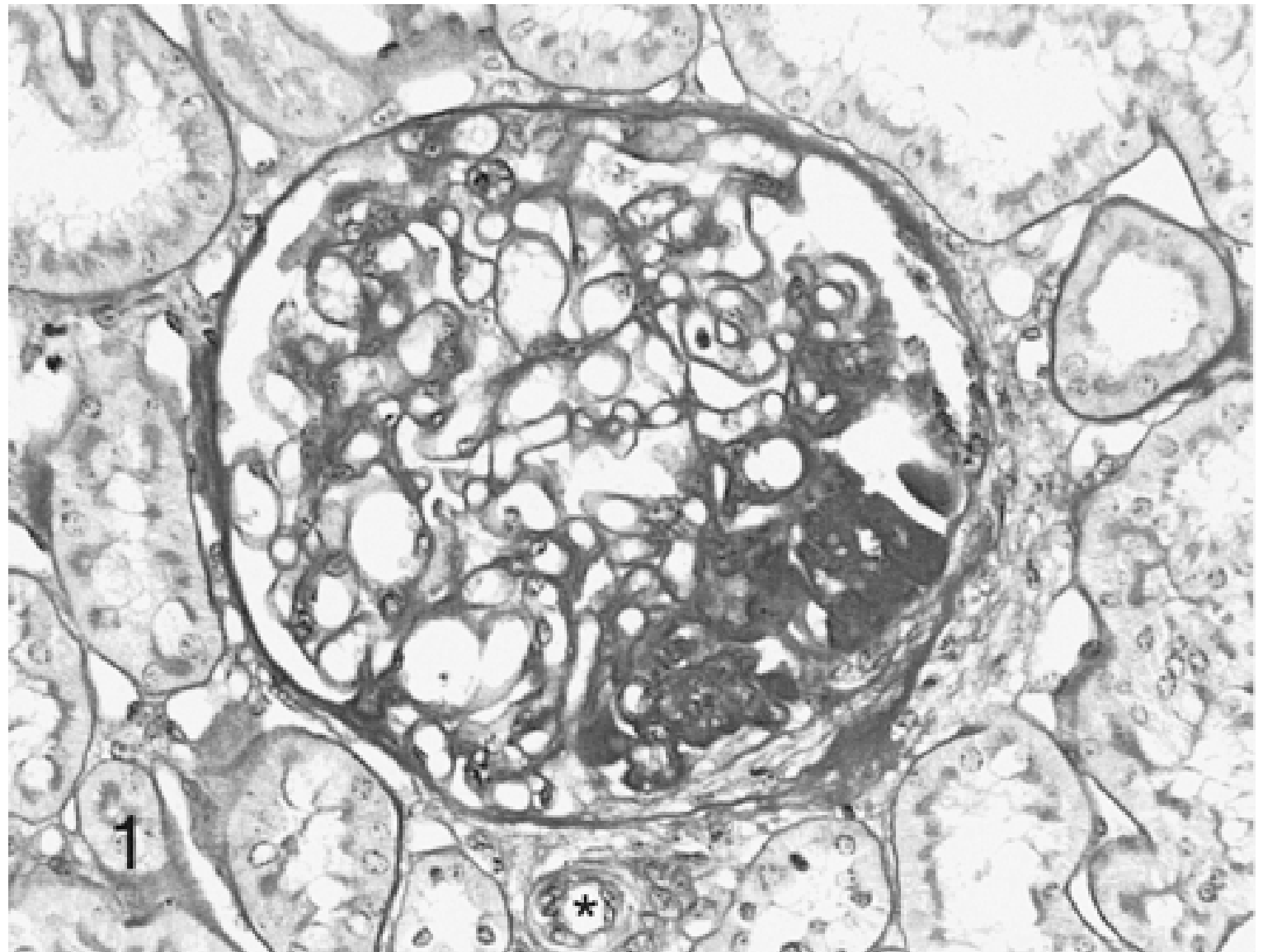


FSGS

-
- FSGS was first described and illustrated in 1925
 - During the 1970s, the differences between FSGS and minimal change in nephrotic patients were emphasized as it became obvious that the prognosis of FSGS was in general poorer
 - Later in the 1980s, however, discussion swung back to emphasizing the many similarities between patients with the two appearances, prompted by the fact that one appearance could evolve into the other in serial biopsies

- 
-
- ❑ FSGS accounts for up to 20% of dialysis patients
 - ❑ The diagnosis of FSGS requires the presence of areas of glomerular sclerosis that are both focal and segmental
 - ❑ The clinical hallmarks include proteinuria, nephrotic syndrome and frequently the progressive loss of renal function
 - ❑ In all forms of FSGS injury is directed to or originates within the podocyte



Primary (idiopathic) FSGS

? Mediated by yet unidentified circulating/permeability factor(s)

Secondary FSGS

1. Familial/genetic

Mutations in nephrin

Mutations in podocin

Mutations in α -actinin-4

Mutations in transient receptor potential cation 6 channel

Mutations in CD2AP

Mutations in WT-1

Mutations in PLCE1

Mutations in SMARCAL1 (Schimke immuno-osseous dysplasia)

Mutations in mitochondrial proteins (mitochondrial cytopathies)

Mutations in β 4 integrin (epidermolysis bullosa)

Mutations in tetraspanin 24 (epidermolysis bullosa, deafness)

Mutations in laminin β 2 (Pierson syndrome)

2. Virus-associated

HIV-1 ('HIV-associated nephropathy')

Parvovirus B-19

SV40

Cytomegalovirus

3. Drug-induced

Heroin ('heroin nephropathy')

Interferon- α

Lithium

Pamidronate

Sirolimus

4. Mediated by adaptive structural–functional responses

Reduced renal mass

Oligomeganephronia

Unilateral renal agenesis

Renal dysplasia

Reflux nephropathy

Sequela to cortical necrosis

Surgical renal ablation

Chronic allograft nephropathy

Any advanced renal disease with reduction in functioning nephrons

Initially normal renal mass

Hypertension

Atheroemboli or other acute vaso-occlusive processes


Obesity


Cyanotic congenital heart disease

Sickle cell anemia

Clinical features

-
- The significance of a finding of FSGS cannot be interpreted in detail without information on the clinical setting
 - Proteinuria is almost invariable
 - Secondary forms of FSGS rarely present with a full nephrotic syndrome, even if in the presence of quite heavy proteinuria
 - In primary FSGS, macroscopic hematuria is very rare, but microscopic haematuria usual and hypertension common

- 
-
- FSGS shows a remarkable racial predominance accounting for almost two-thirds of AA adults with a nephrotic syndrome
 - Clinically, the most important prognostic feature is whether or not proteinuria resolves, almost always in association with treatment
 - Patients in whom this happens, even if they relapse repeatedly, almost always do well

- 
-
- The only other features that have prognostic value are renal function at the time of investigation and the amount of proteinuria
 - Age, sex, race and hypertension do not seem to affect prognosis
 - In renal biopsy specimen the major prognostic factor is the presence and extent of tubulo-interstitial damage

Histologic variants

Collapsing variant

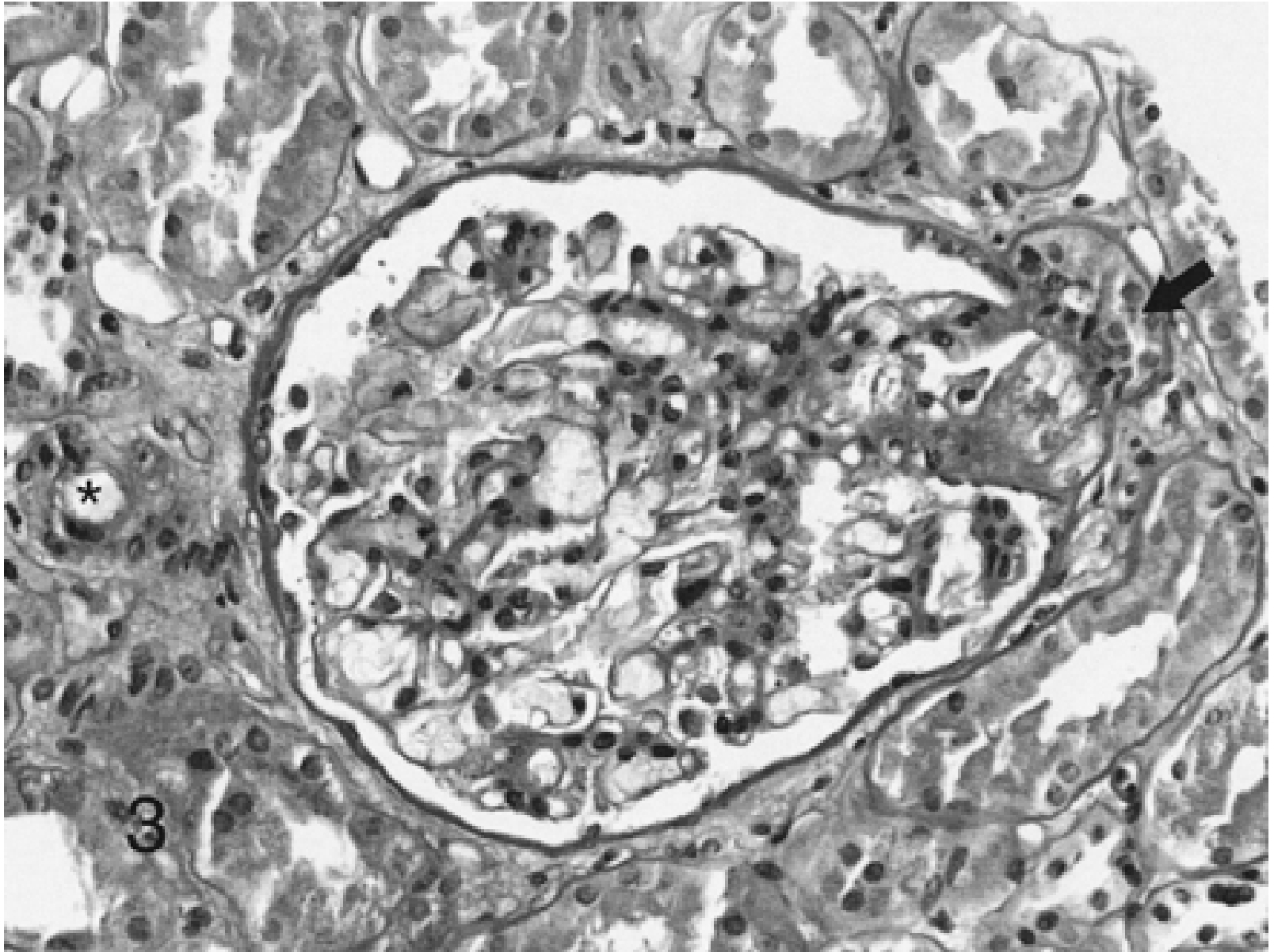
- There is at least one glomerulus with tuft collapse and overlying visceral epithelial cell hypertrophy and hyperplasia
- Characterized by:
 - Black racial predominance
 - Severe markers of nephrotic syndrome
 - Poor response to steroid
 - A rapidly progressive course to renal failure

Causes

- HIV
- Parvovirus B19
- Acute cytomegalovirus infection
- Erythrophagocytosis syndrome
- Interferon therapy
- Pamidronate toxicity
- Acute vaso-occlusive injury
- Rare familial forms

Tip variant

- Defined by at least one segmental lesion involving the tip domain
- Is more common in Caucasian adults
- Tends to present with abrupt onset of full nephrotic syndrome
- There is usually less tubulointerstitial injury
- Responds better to steroids and there is usually preservation of renal function
- Most cases are idiopathic



Perihilar variant

- Defined as perihilar hyalinosis and sclerosis involving the majority of glomeruli with segmental lesions
- This pattern may occur in primary FSGS but it is particularly common in secondary forms where it is usually accompanied by glomerular hypertrophy
- Foot process effacement is usually milder and more focal than in primary FSGS

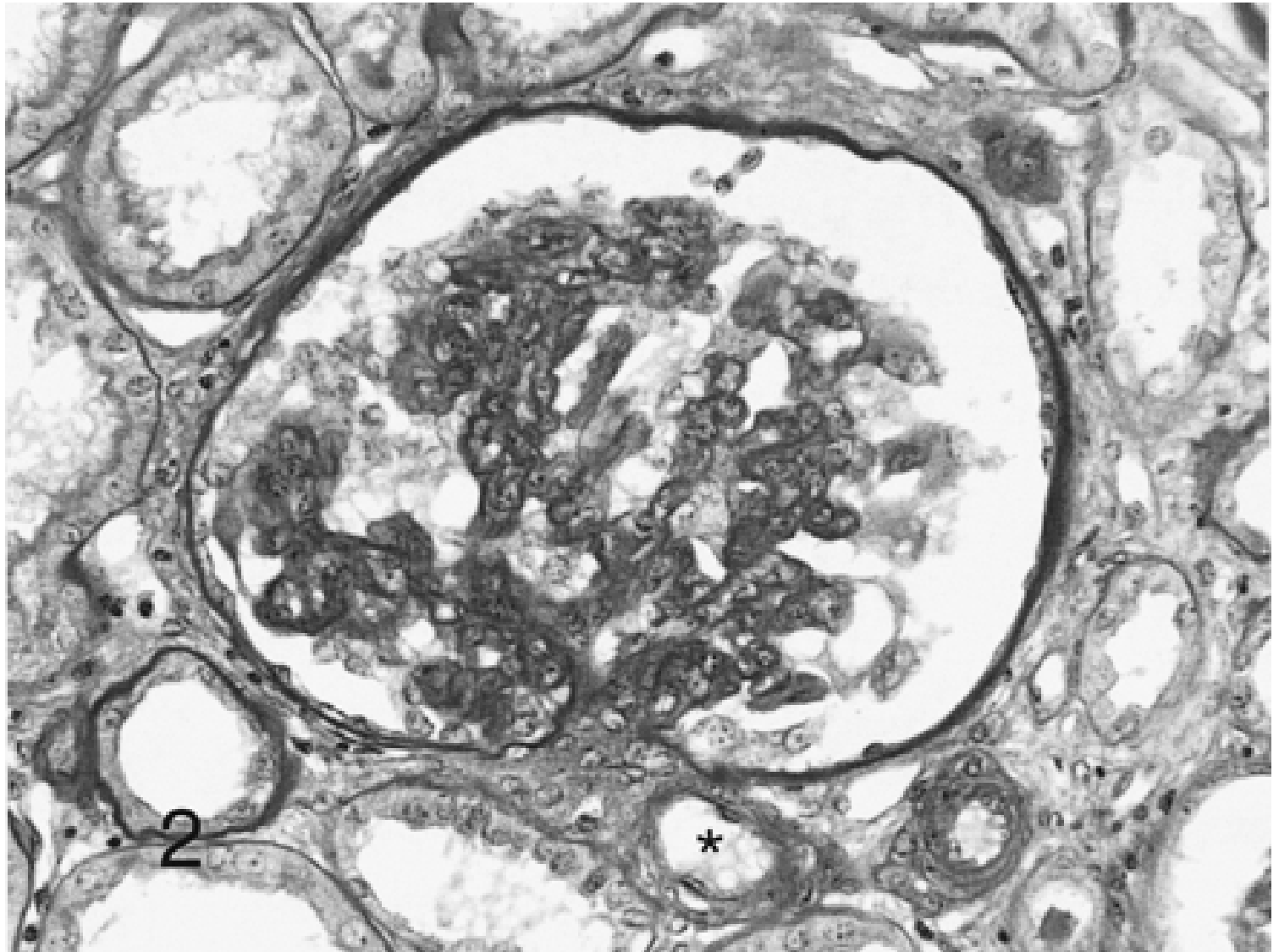


Causes

- Obesity
- Reflux nephropathy
- Hypertension
- Sickle cell anemia

Cellular variant

- The least common and the least well understood
- Cellular lesions show segmental endocapillary hypercellularity, associated with variable glomerular epithelial cell proliferation
- Represents an early stage in the evolution of segmental sclerosis
- The majority of cases are idiopathic



FSGS NOS

- Is the most common form of FSGS
- Term applies to a renal biopsy that does not meet defining criteria for any other variant

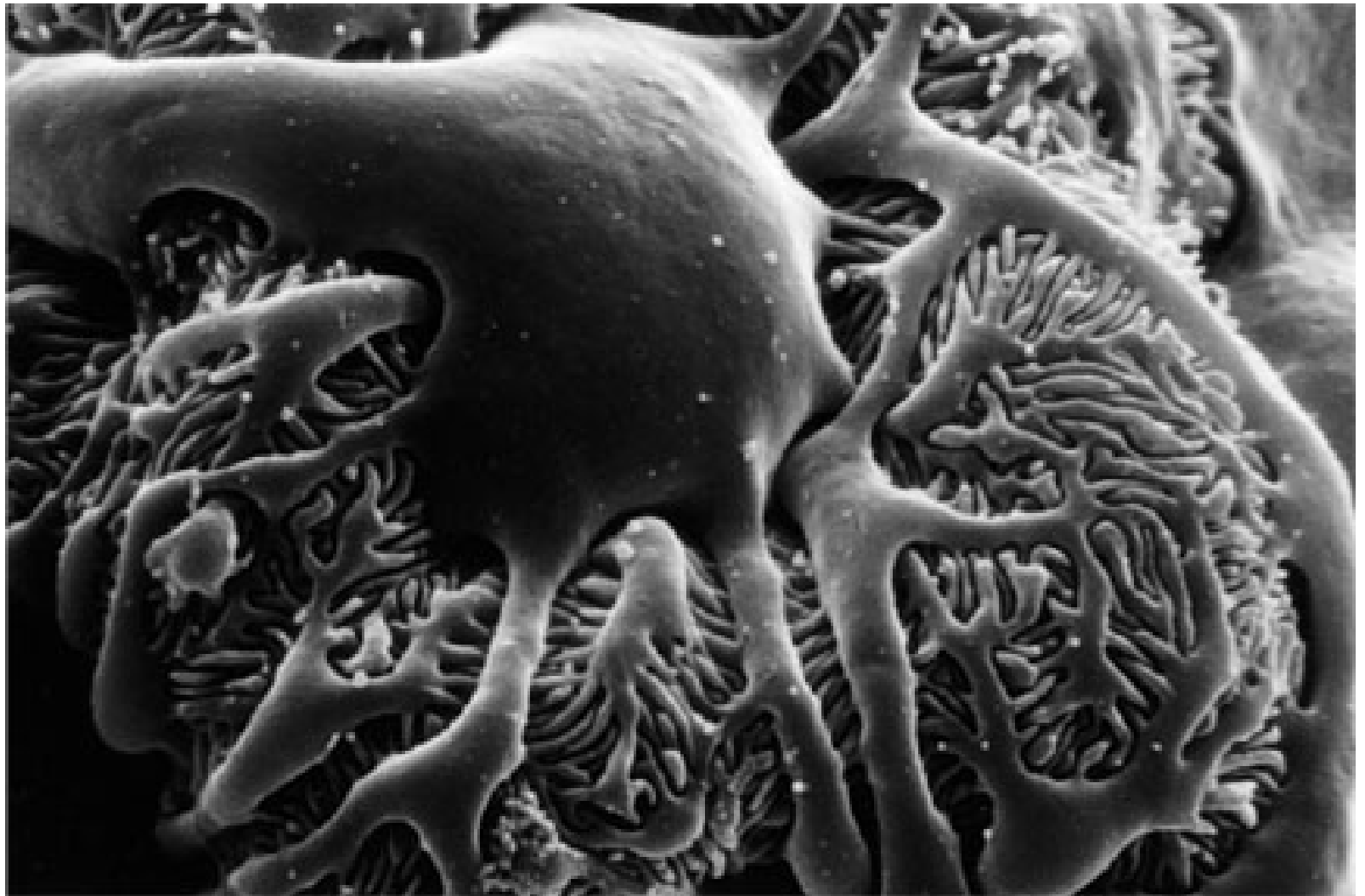-
- Among 716 cases of FSGS from Columbia registered from 2000–2004
 - 4.5% were cellular
 - 9.4% were tip lesion
 - 23.7% were collapsing
 - 62.3% were NOS or perihilar


 - Among 225 patients with primary FSGS and outcome data, remission rates were
 - 13% for collapsing FSGS
 - 44% for cellular
 - 76% for tip lesion

 - Collapsing FSGS had the highest rate of progression to end-stage renal disease (65%), compared to 35% for NOS, 28% for cellular and 6% for tip lesion


A podocytopathy


-
- ❑ The podocyte is a highly differentiated epithelial cell that covers the surface of the glomerular tuft
 - ❑ It has a large cell body from which primary processes emerge and give rise to a highly ordered system of interdigitating foot processes bridged by slit diaphragms
 - ❑ Podocytes cover the outer aspect of the glomerular basement membrane



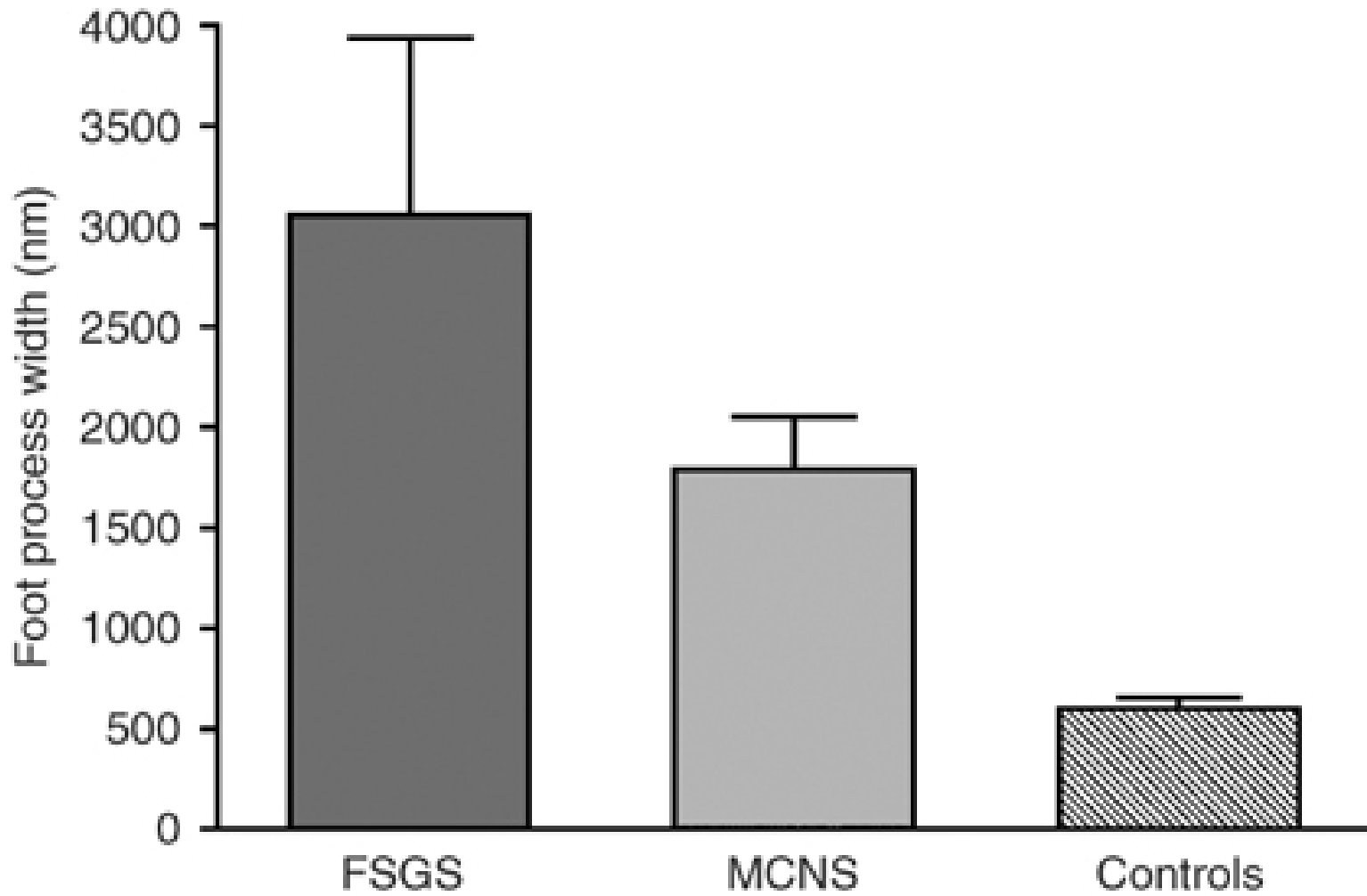
- 
-
- Podocyte foot process effacement is an invariable feature of proteinuric glomerular diseases
 - The response of the podocyte to injury is an effacement of the foot processes owing to reorganization of the actin cytoskeleton
 - This process may follow interruption of signaling networks arising from four possible subcellular domains: the actin cytoskeleton, slit diaphragm, apical membrane, or basal membrane

-
- Signal transduction through the slit diaphragm regulates critical cellular processes such as actin cytoskeletal dynamics, cell cycle regulation, cell polarity and programmed cell death
 - When critical levels of cell stress are reached, the podocyte may undergo apoptosis or detachment, creating denuded segments of GBM

- 
-
- ❑ Podocyte loss is not replenished leading to podocytopenia and progressive glomerulosclerosis
 - ❑ Cells with podocyte-specific markers have been detected free within the urinary space and in the urine
 - ❑ This provides morphologic evidence of ongoing podocyte loss in both primary and recurrent FSGS
 - ❑ Podocyturia has been proposed as a clinical marker of disease activity

- 
-
- ❑ The degree of foot process effacement appears to be independent of the level of proteinuria but depends on the underlying disease
 - ❑ It has been shown that the mean percentage of the glomerular surface area affected by foot process fusion was less in patients with FSGS secondary to maladaptive responses compared to idiopathic FSGS

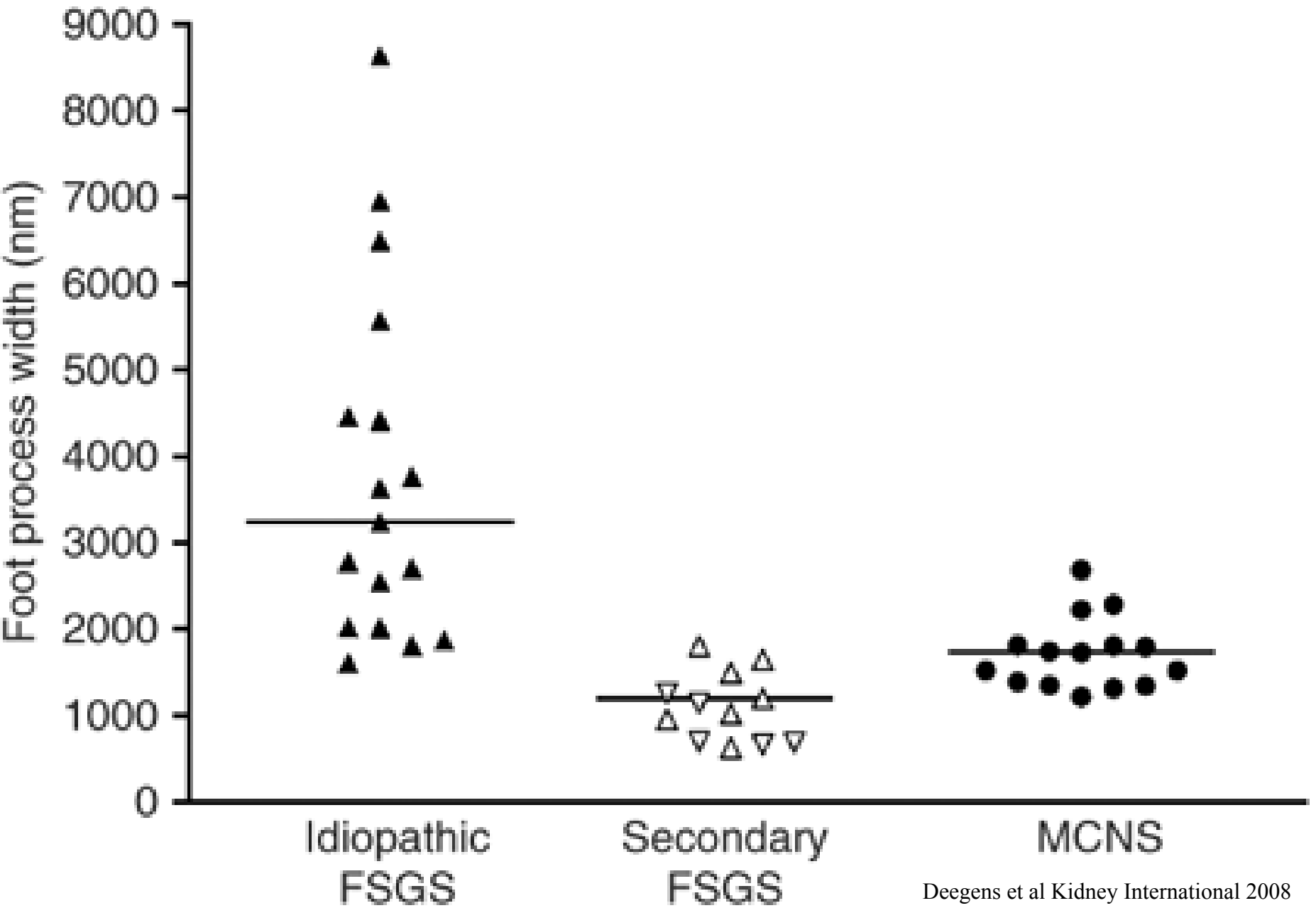
-
- 24 patients with biopsy proven FSGS were included in the study
 - For comparison renal biopsy material of 15 patients with MCNS and 12 control patients was used
 - A clinical diagnosis of FSGS secondary to maladaptive responses was made in patients with
 - an identifiable cause
 - nephrotic range proteinuria (>3 g per day) with a serum albumin >3.5 in two measurements in the 3-month period before and after renal biopsy

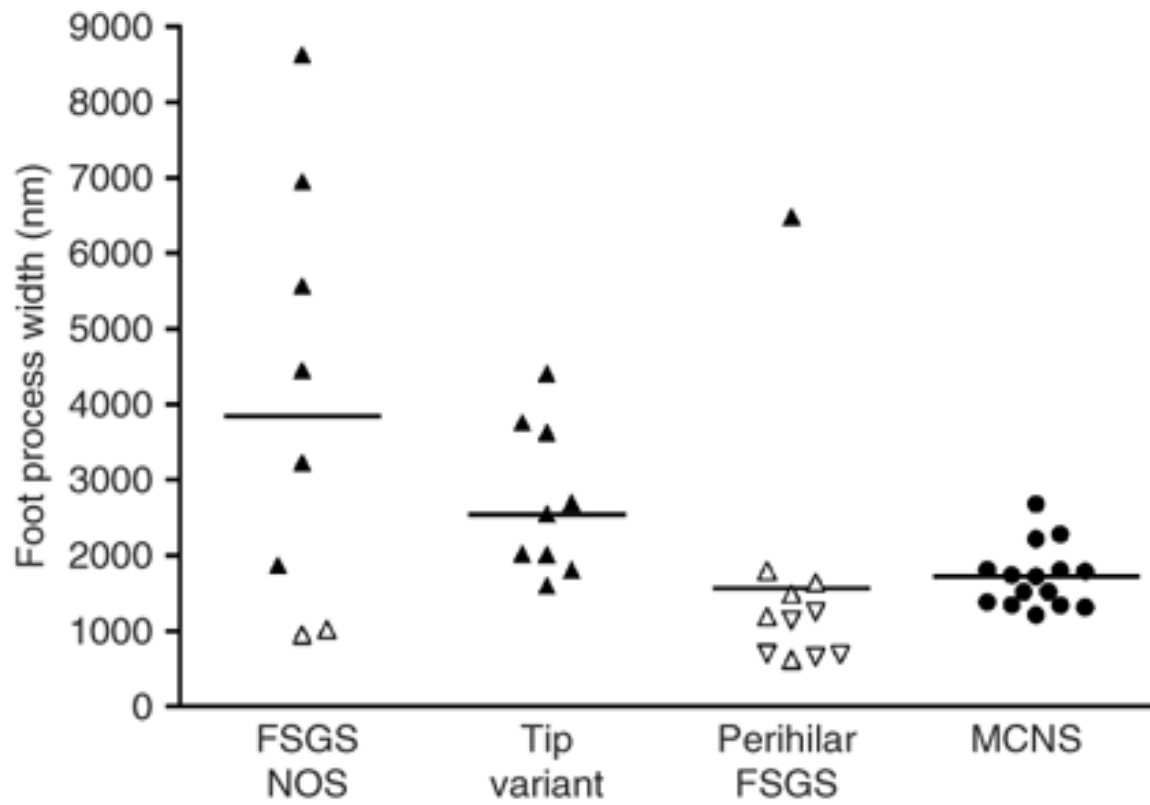


-
- Foot process width correlated with:
 - type of disease
 - age at biopsy


 - But not with:
 - serum albumin
 - serum creatinine
 - treatment with ACEi
 - or proteinuria

 - On multivariate analysis, type of disease (MCNS, idiopathic or secondary FSGS) was the only determinant of FPW ($P < 0.001$).



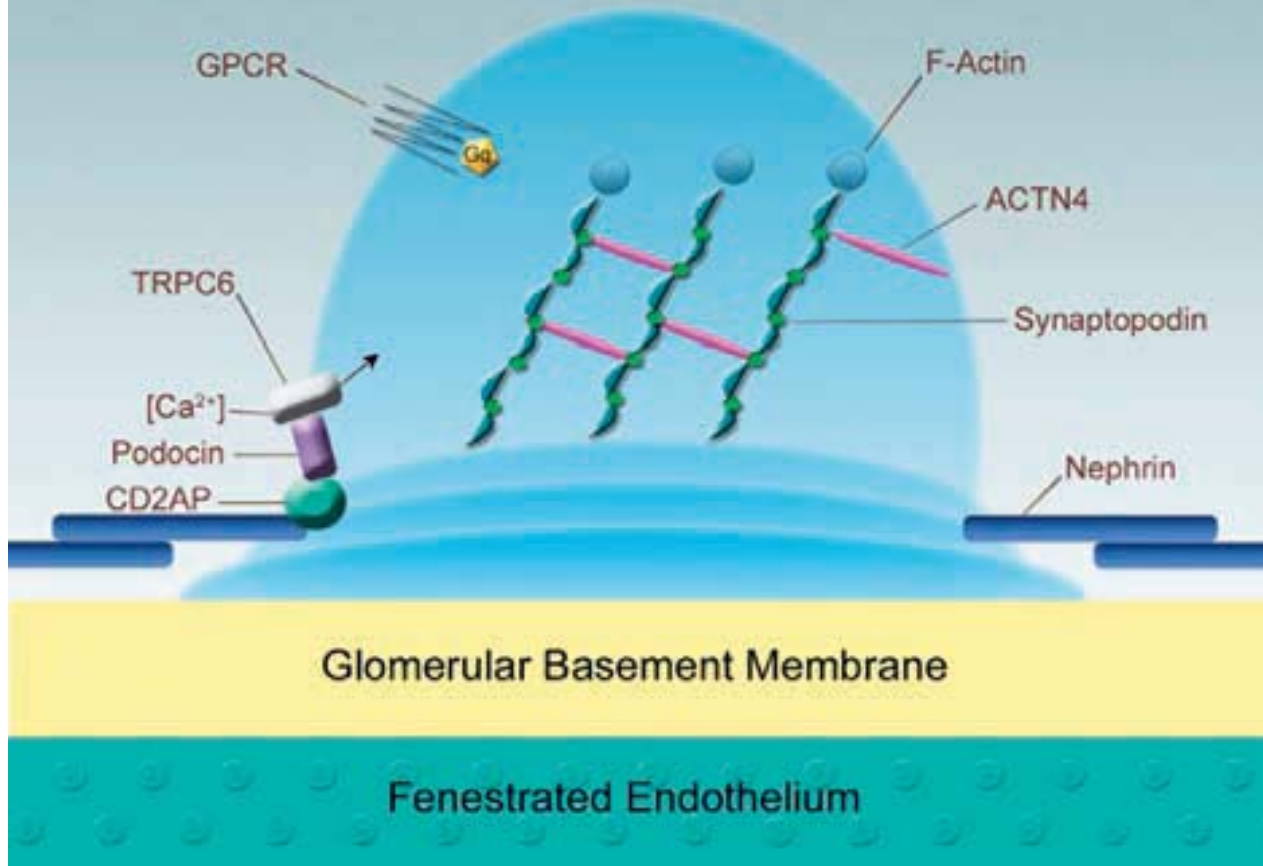

Genetics


- 
-
- The NPHS1 gene product Nephrin is predominantly expressed in the podocyte, where it localizes to the slit diaphragm
 - NPHS2, encodes a membrane protein named podocin
 - Podocin has been localized to the slit diaphragm and has now been shown to interact directly with nephrin

-
- Mutations in ACTN4, the α -actinin-4 gene, cause a slowly progressive form of disease characterized by dominant inheritance, generally subnephrotic proteinuria, and renal insufficiency
 - NPHS1-, NPHS2-, and ACTN4-associated disease forms a spectrum from onset before birth, to childhood onset, to adult onset disease

Podocyte Foot Process



FSGS and transplantation

- 
-
- Recurrence of severe FSGS in renal allograft recipients presents a major challenge to transplant physicians
 - The incidence of recurrence is generally accepted to be between 20% and 30%
 - Risk factors for recurrence include a rapid progression of the primary disease to end-stage renal failure and age less than 15 years





Characteristics of recurrence include

- early onset of nephrotic range proteinuria after allografting
- frequent loss of the allograft
- a high frequency of recurrence in subsequent allografts

-
- Some investigators have identified a circulating factor called the FSGS factor that appears to be associated with recurrence after transplantation
 - Plasmapheresis was therefore attempted with varying success and patients response seemed to be completely individual
 - Other studies have added cyclophosphamide and/or mycophenolate mofetil to the plasmapheresis protocol with also variable success
 - Because some patients show complete recovery with plasmapheresis, individuals who develop recurrent FSGS after transplantation usually are given a trial of plasmapheresis therapy

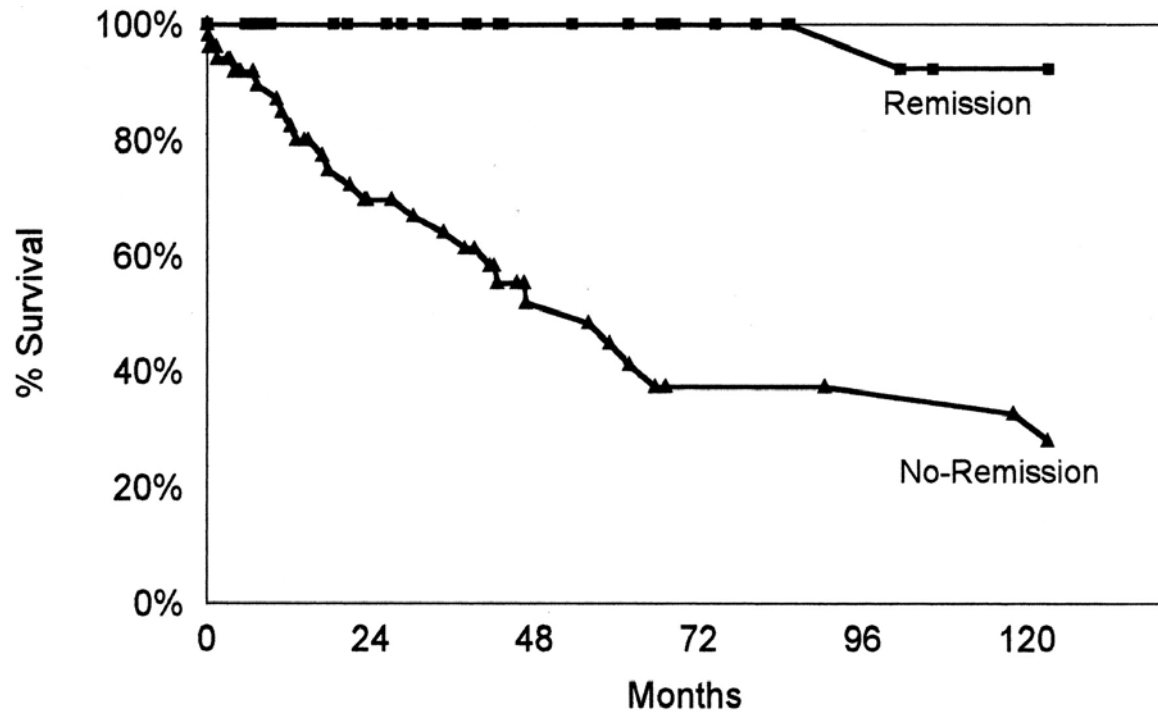
Treatment

- 
-
- Prednisone 1mg/kg is usually given to nephrotic pts with primary FSGS
 - The duration of treatment and the rapidity of the steroid taper depends on whether pts achieve partial or complete remission
 - Cyclosporine is used in pts who can not tolerate steroids or are steroid resistant or steroid dependent

- 
-
- Retrospective, clinicopathologic analysis of adult patients who had primary FSGS and nephrotic-range proteinuria included 87 patients
 - Three morphologic forms of FSGS were included: the classic scar, the cellular lesion, and the tip lesion

Characteristics	Classic FSGS	Cellular Lesion	Tip Lesion	<i>P</i>
<i>n</i>	36	40	11	
Black	23 (64%)	29 (73%)	6 (55%)	NS
Male	23 (64%)	23 (58%)	5 (45%)	NS
Age (yr)	40 ± 17	38 ± 16	53 ± 17	<0.05
Hypertension	18 (50%)	18 (45%)	8 (73%)	NS
Creatinine (mg/dl)	1.7 ± 0.8	2.5 ± 2.1	1.6 ± 0.7	NS
Renal insufficiency	19 (53%)	27 (68%)	6 (55%)	NS
Proteinuria (g/d)	6.6 ± 3.5	12.5 ± 9.9 ^b	8.6 ± 4.0	<0.05
Proteinuria >10 g/d	6 (17%)	17 (43%) ^b	3 (27%)	<0.05
Presentation to biopsy (mo)	13 ± 29	9 ± 19	3 ± 5	NS

-
- There was no significant difference in the response to steroid treatment among the three groups, with a remission rate of >50% in all patients who received steroid therapy
 - In patients who entered remission, there was a significantly improved renal survival compared with patients who did not enter remission, irrespective of the histologic lesion
 - However, the renal survival among nephrotic patients who did not enter remission was significantly poorer for patients with cellular and tip lesions compared with patients with classic scars



Month	0	12	24	36	48	60	72	84	96	108	120
Remission	36	33	30	27	23	22	18	16	14	12	12
No-Remission	51	37	27	24	16	13	10	10	9	9	8

-
- The best predictor of outcome in nephrotic patients with primary FSGS, irrespective of histologic variant, is a remission in proteinuria
 - Spontaneous remissions are rare and the use of conservative management alone rarely leads to remission in nephrotic patients with FSGS
 - Attempts to determine which patients are most likely to benefit from a trial of therapy have failed to demonstrate any clinical or histologic features at biopsy that reliably predict response
 - Patients who have primary FSGS and remain nephrotic despite conservative treatment should receive a trial of steroids or immunosuppressive therapy

Conclusion

- ❑ Some patients with FSGS respond to steroids, some do not
- ❑ Some patients present with nephrotic syndrome others with mild proteinuria
- ❑ Some present in childhood, some as adults
- ❑ FSGS can be primary or secondary to other primary processes
- ❑ Some, but not all, FSGS recurs in transplanted kidneys
- ❑ Histologic patterns of injury such FSGS should not be considered a disease but rather a description of kidney biopsy specimens at particular points in time